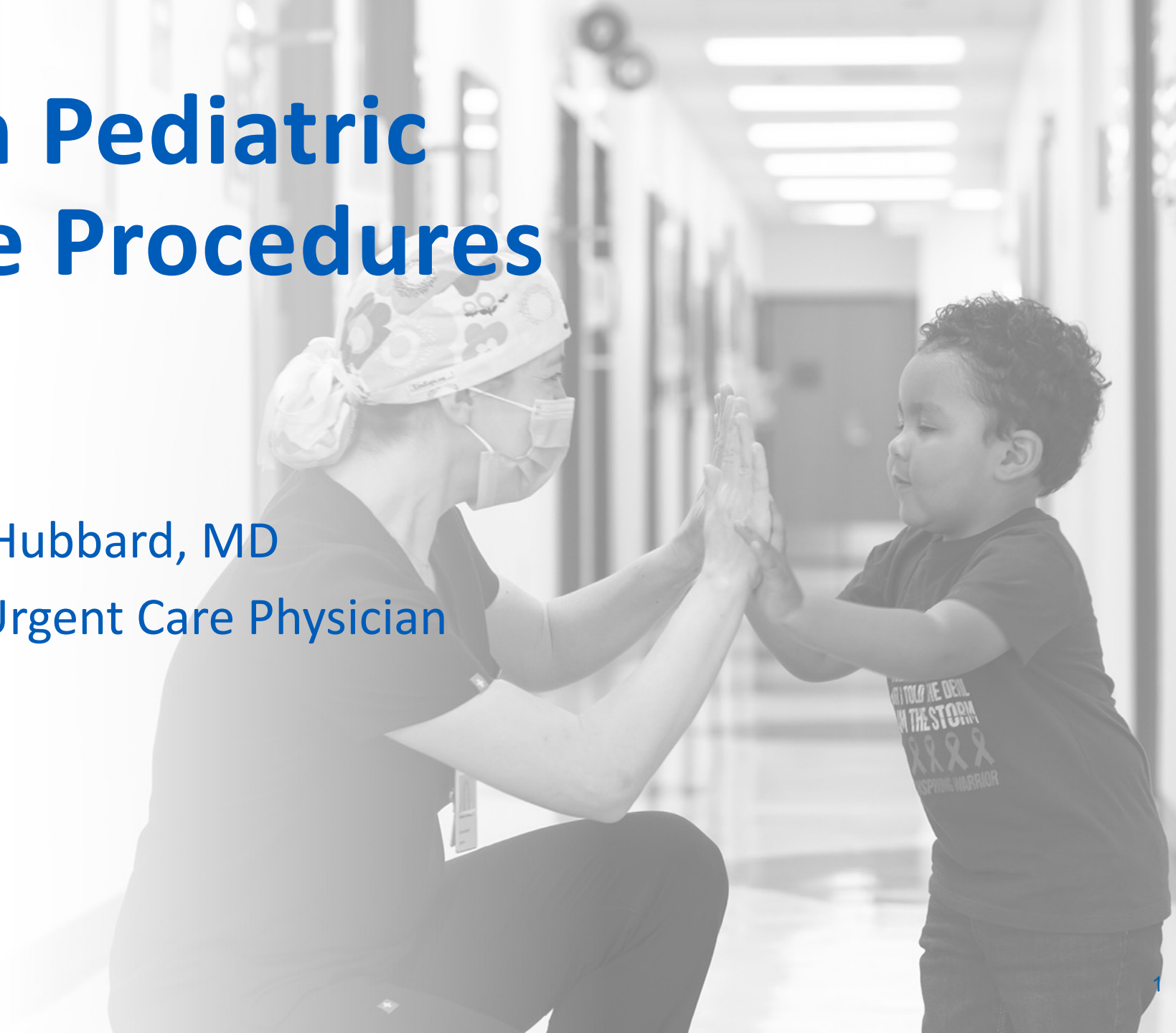


Common Pediatric Urgent Care Procedures

Dr. James Hubbard, MD
Children's Mercy Urgent Care Physician



Disclosure

- I have no relevant conflicts of interest or financial agreement disclosures
- I will no discuss any off-label uses of any medications or devices

Overview and Basic Principles



Visualization

- Adequate lighting
- Make sure wound is free of foreign bodies

Restraint

- Physical restraint
 - Wrapping
 - Papoose board
- Chemical restraint
 - Intranasal midazolam
 - Internasal fentanyl

Pain Control

- Local block
- Area specific blocks

Comfort Level

- Don't be a hero
- Refer to ER/Specialist if you are not comfortable

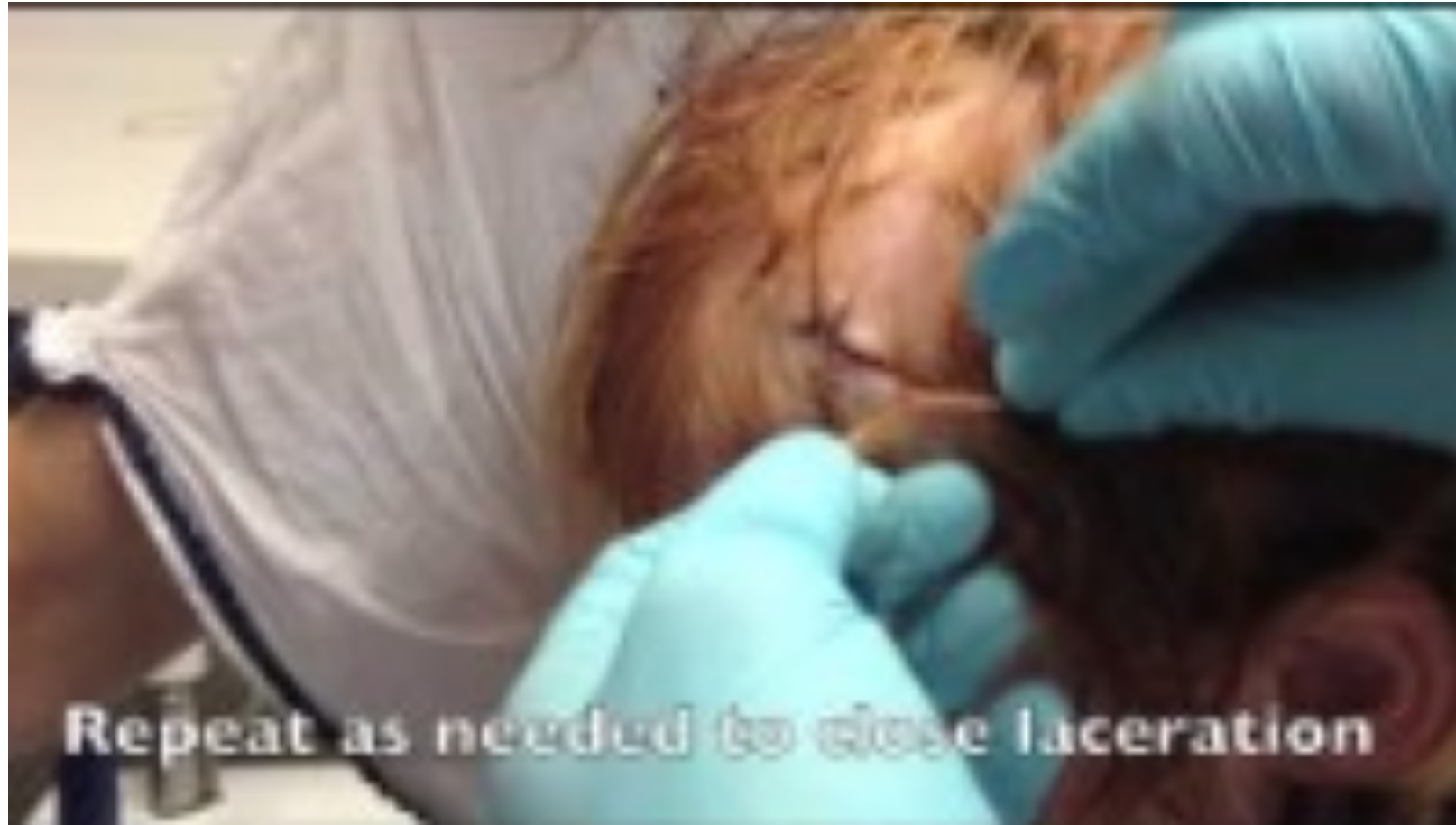Specific Procedures

- Scalp Laceration
- Ear Procedures
- Nasal Foreign Body
- Lip Lacerations
- Nursemaid Elbow
- Finger Lacerations
- Leg Lacerations
- Ingrown Toenail

Scalp Lacerations

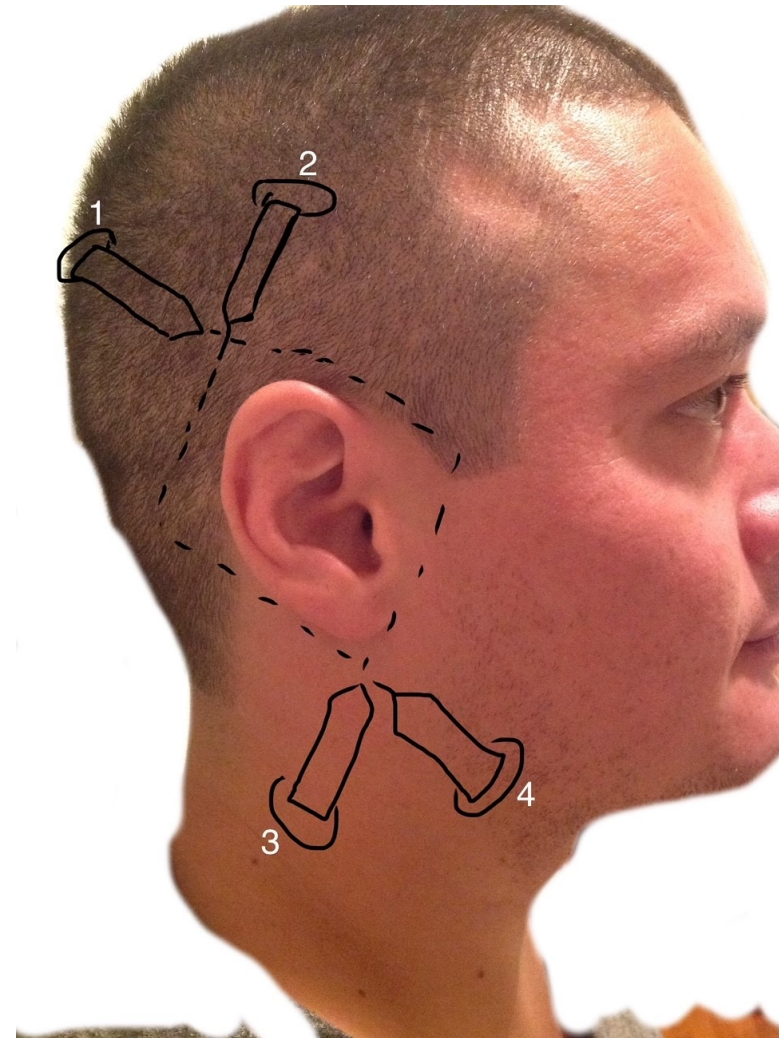
- Staples
- Hair tie technique
 - No local anesthesia needed
 - No follow up visits
 - Use clamps for short hair

Scalp Laceration – Hair Tie Technique



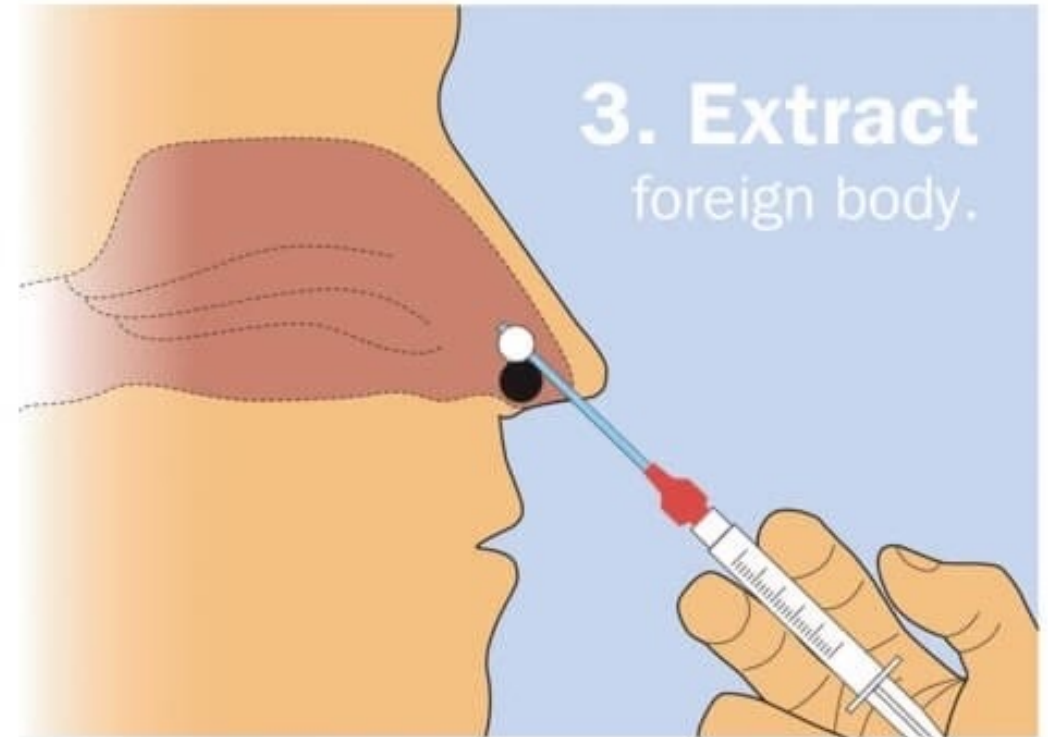
Ear Procedures

- Upper/lower block
- Removing earrings
- Ear foreign body



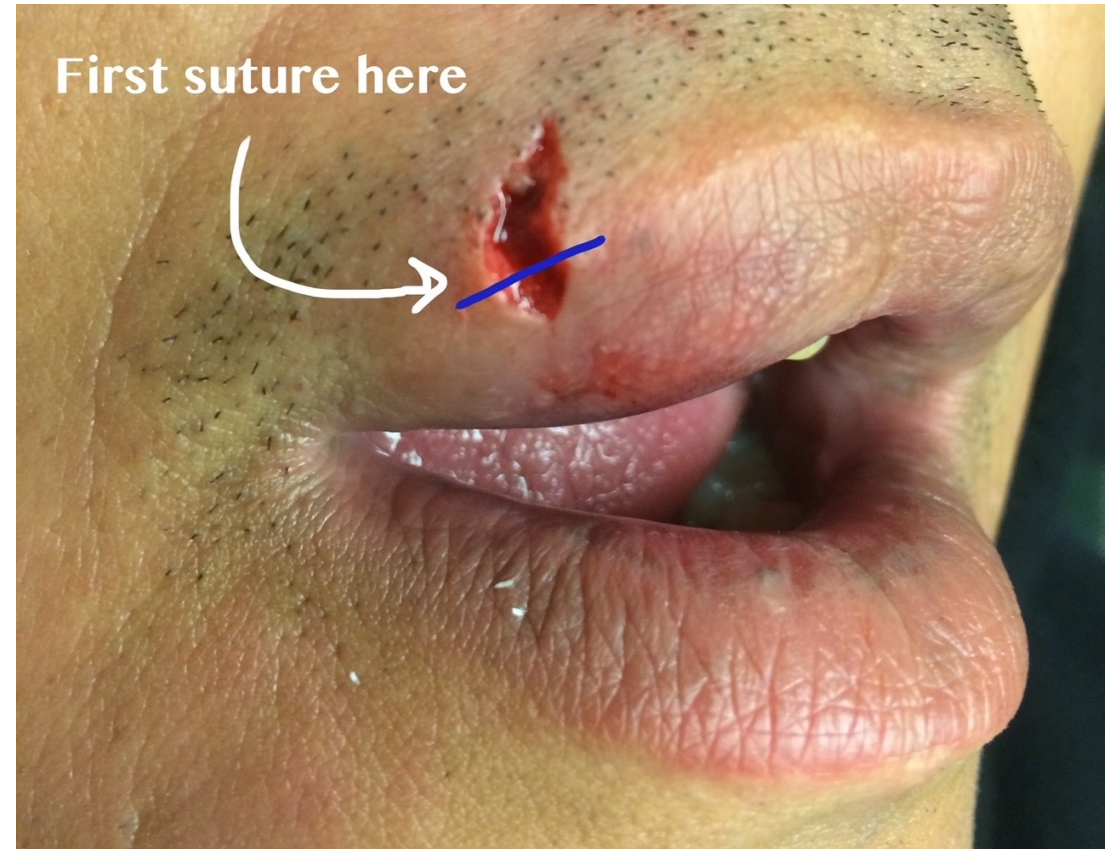
Nasal Foreign Body

- Katz extractor
- Consider decongestant nasal spray
- “Mother’s Kiss”



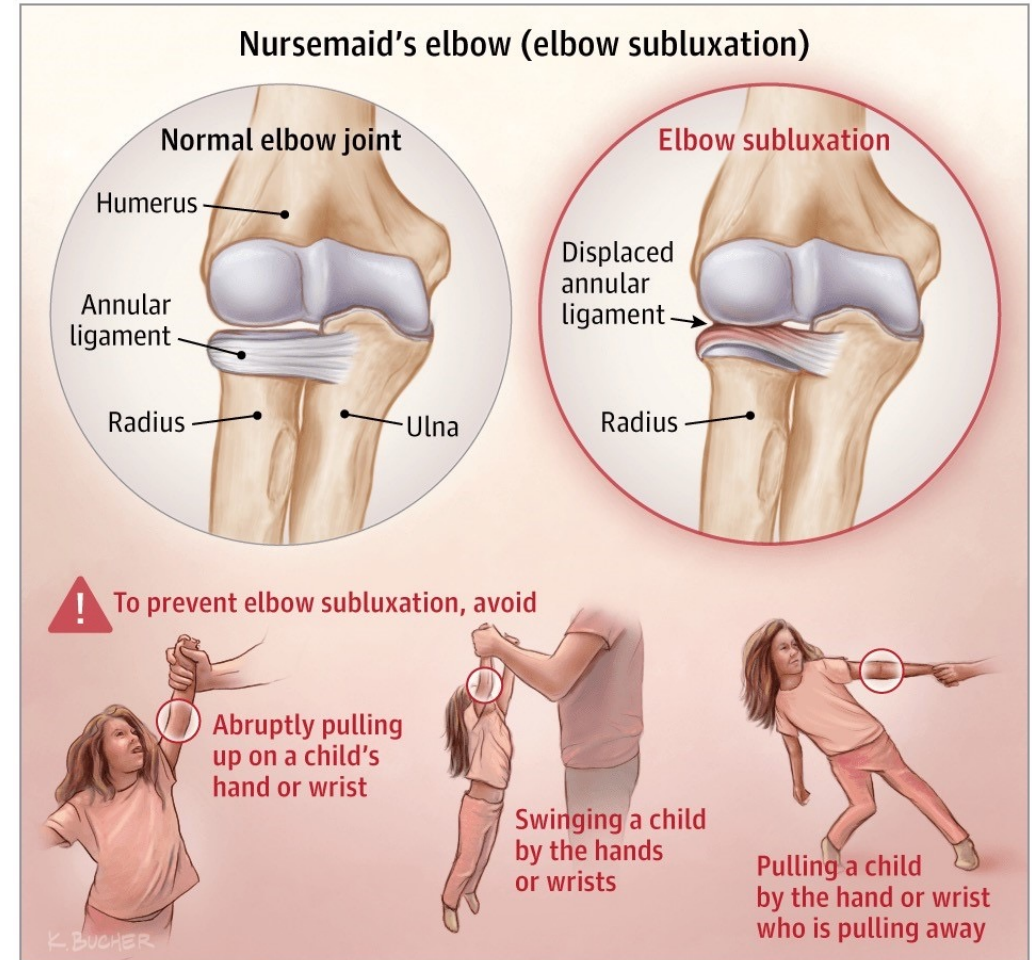
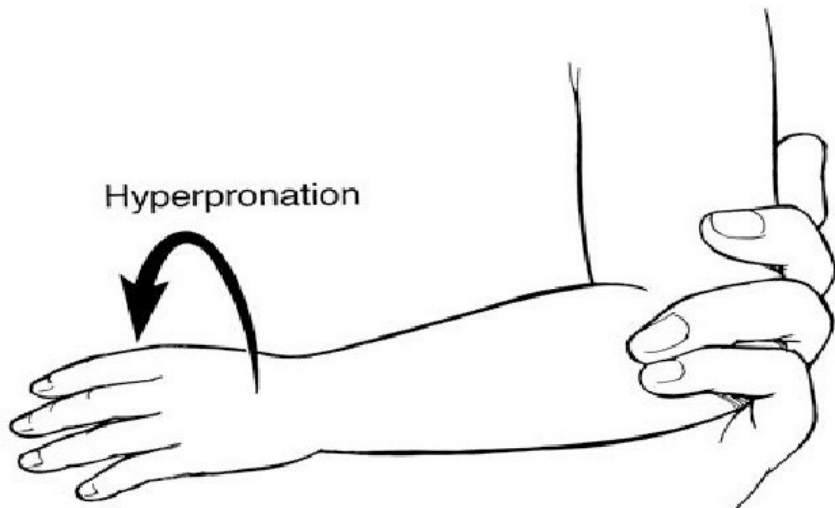
Lip Lacerations

- Vermillion border
- Non-absorbent sutures
- Consider nerve block
- Careful inspection for foreign body
- Gentle (if any) irrigation



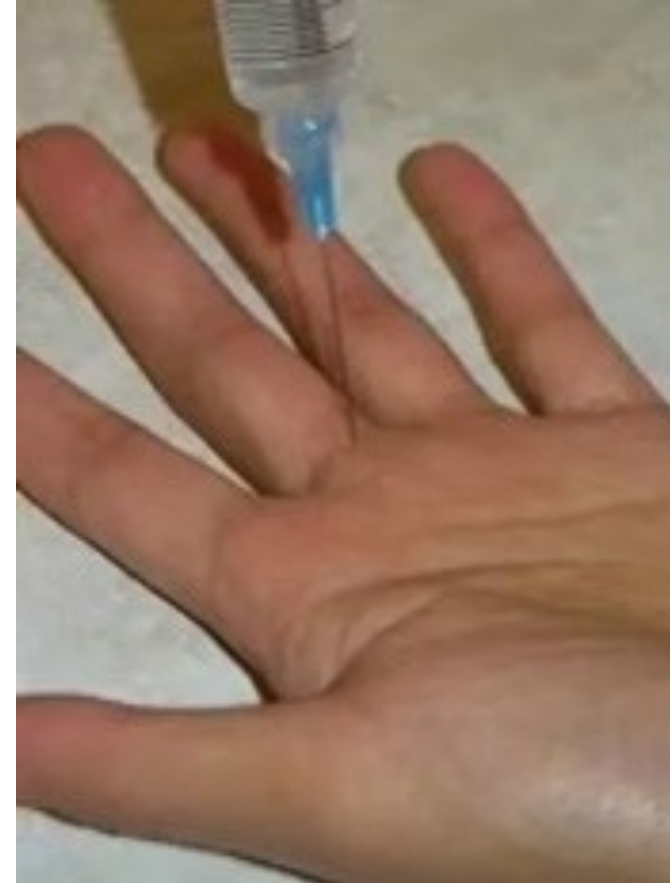Nursemaid Elbow

- Clinical presentation
- Flexion pronation
- Hyperpronation



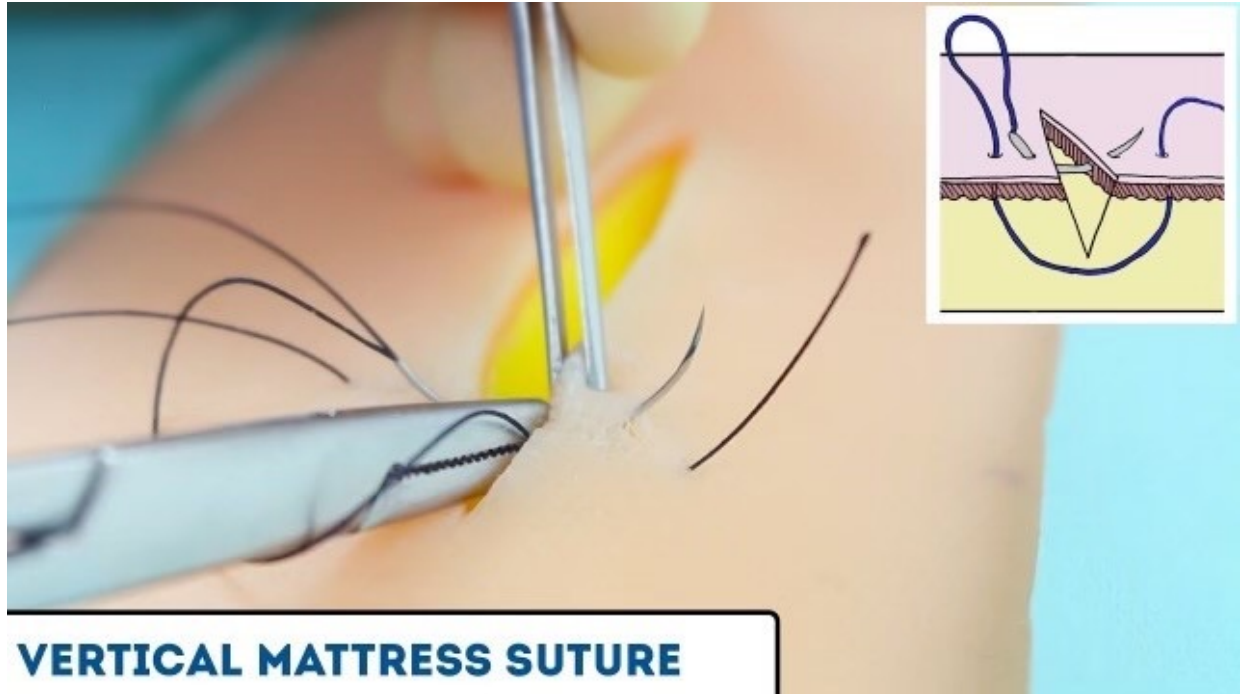Finger Lacerations

- Tourniquet
- Digital block
 - Ring block
 - Transthecal block



Extremity Lacerations

- Tend to be gaping
- Longer healing time
- Mattress suture
 - Vertical
 - Horizontal



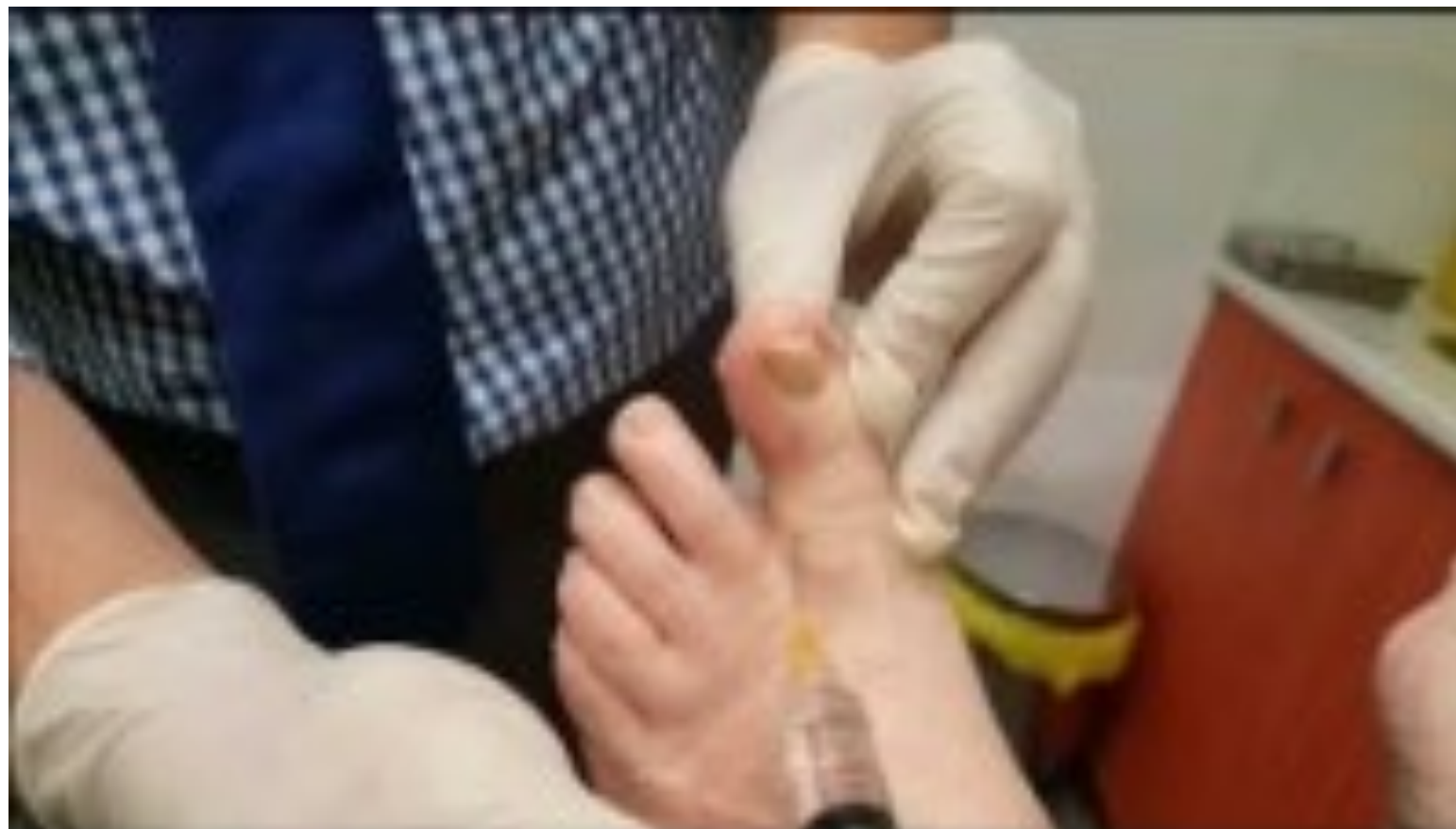Corner Suture



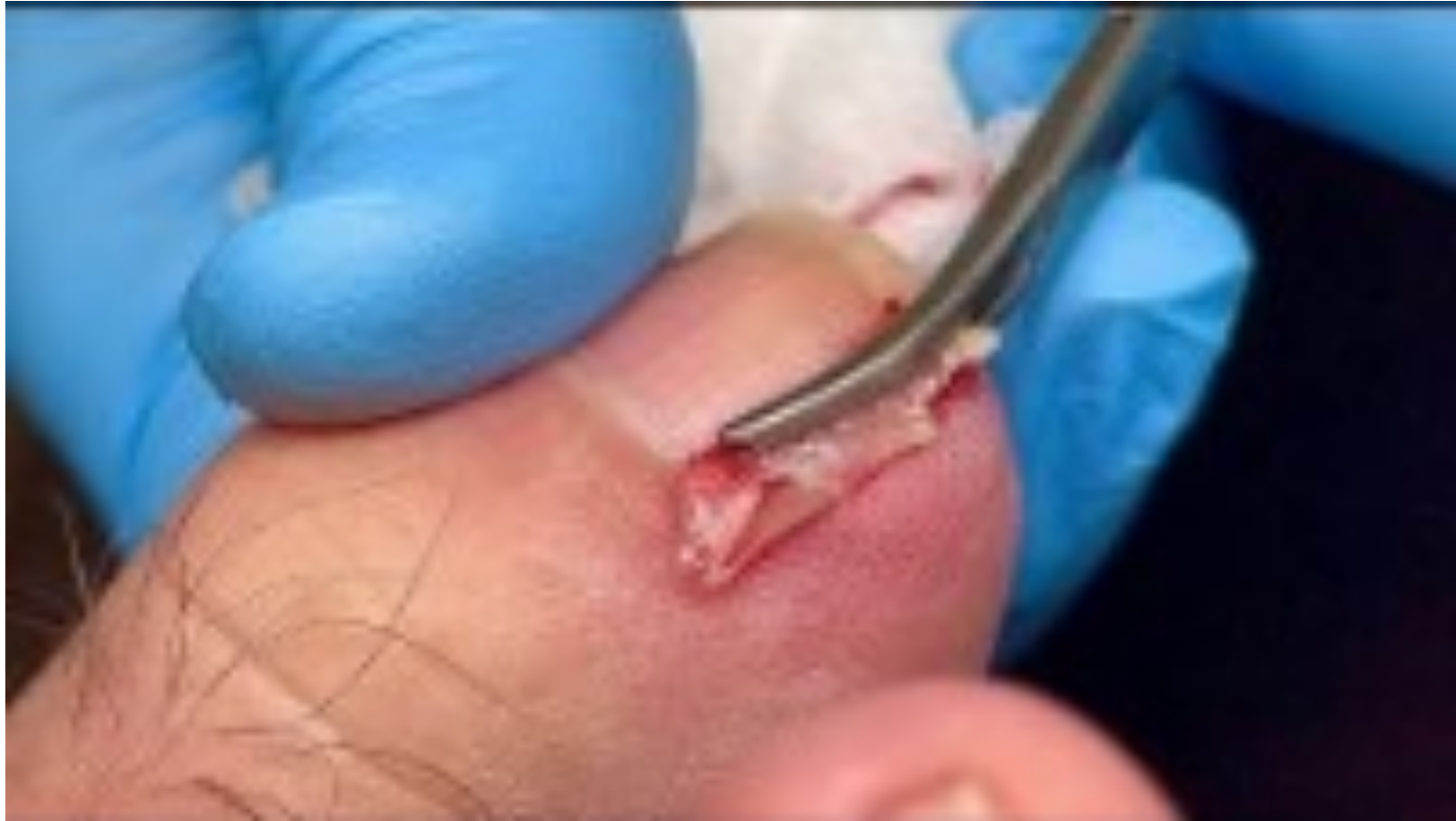Ingrown Toenail

- Anesthesia
- Procedure
- Follow up care
- Conservative management

Digital Block



Ingrown Toenail





Children's Mercy
KANSAS CITY